

Meeting abstract

Open Access

2096 Phase contrast planimetry of valve area in aortic stenosis

Kieran R O'Brien*¹, Ruvin Gabriel², Andrew Kerr², Brett Cowan¹ and Alistair Young¹

Address: ¹The University of Auckland, Auckland, New Zealand and ²Middlemore Hospital, Auckland, New Zealand

* Corresponding author

from 11th Annual SCMR Scientific Sessions
Los Angeles, CA, USA. 1–3 February 2008

Published: 22 October 2008

Journal of Cardiovascular Magnetic Resonance 2008, **10**(Suppl 1):A365 doi:10.1186/1532-429X-10-S1-A365

This abstract is available from: <http://jcmr-online.com/content/10/S1/A365>

© 2008 O'Brien et al; licensee BioMed Central Ltd.

Introduction

Correct estimation of aortic valve area (AVA) is essential to decide when an aortic stenosis patient should undergo surgery. Traditional planimetry assumes that the AVA can be directly traced via the signal loss seen in a magnitude image. It has previously shown good correlation; however it is difficult to accurately define the signal loss boundary and is time consuming. Recently similar approaches have been explored using the phase contrast (PC). The assumption being that a clear distinct boundary for differentiating the high velocity pixels of the jet can be seen.

Purpose

To investigate the applicability of phase contrast planimetry approaches by investigating the area vs velocity curve for distinct and consistent features that reflect AVA in a constant flow phantom and in-vivo.

Methods

A constant flow phantom has previously been constructed. It consists of a straight PVC pipe (Internal Diameter (ID) 28 mm) with a concentric circular obstruction placed in the flow to simulate a stenotic valve. Two different obstructions were used (ID = 12 mm, 15 mm) and were imaged at 35 mm and at one orifice diameter downstream from the constriction at a flow rate of 400 mL/s. 15 patients with moderate-severe aortic stenosis were used to acquire images at the valve plane and 1 cm downstream of the valve plane.

All experiments were conducted on a Siemens 1.5 T Avanto system. A retrospectively gated velocity encoding technique was used – for the constant flow phantom triggering was applied off an artificial ECG trace. Parameters were TE/TR of 2.79 msec/50.85 msec, typical voxel size of 1.17 × 1.17 × 6, matrix size 192 × 256 and a VENC of 500 cm/sec.

The data was analysed by contouring around the edge of the vessel and plotting (inverse) cumulative area (vessel area – cumm.area) vs velocity. If the assumption that a distinct boundary of the jet can be seen in the phase image then this should be seen as a feature in the cumm.area vs velocity curve, figure 1, as either a "elbow" indicating the rapid increase of velocity at the edge of the jet (A) or a "sudden drop off" to indicate pixels within the jet (B). In the patients only 1–3 mid-systolic frames were chosen for analysis.

Results

In the constant flow phantom the extent to which an elbow is seen depends on the size of the orifice and the location of the image plane. The more consistent elbow is seen with the smaller constriction and at 1 diameter downstream of the constriction. The larger constriction had no discernable features and instead smoothly tailed off to zero. No sudden drop-off was seen in either phantom. Similar results were seen in vivo. Some patients appeared to show a feature but it was more often that the cumm.area vs velocity curved off smoothly to zero.

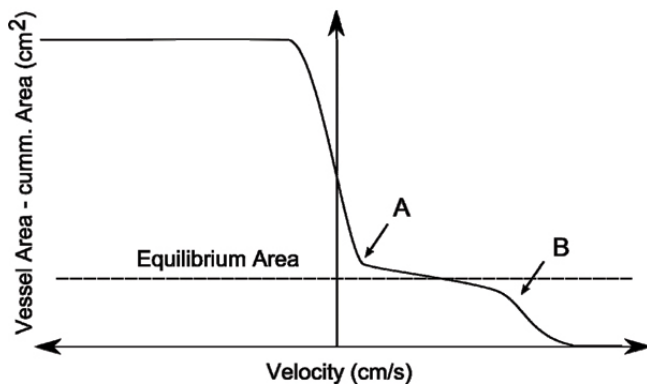


Figure 1
Idealised cumulative area vs velocity curve showing possible features that should be present to indicate a clear boundary for tracing pixels within a jet using phase contrast planimetry.

Conclusion

The results show that any boundary used to trace around the jet pixels in a phase contrast image is very subjective. We found that in most cases in-vivo and experimentally that there is a smooth change in velocity from regions outside the jet to in the jet. This means that tracing around "jet pixels" to directly measure AVA would be very dependent on the user and the image display settings. Though good correlations could be found this is not an appropriate method for accurately quantifying AVA.

Publish with **BioMed Central** and every scientist can read your work free of charge

"BioMed Central will be the most significant development for disseminating the results of biomedical research in our lifetime."

Sir Paul Nurse, Cancer Research UK

Your research papers will be:

- available free of charge to the entire biomedical community
- peer reviewed and published immediately upon acceptance
- cited in PubMed and archived on PubMed Central
- yours — you keep the copyright

Submit your manuscript here:
http://www.biomedcentral.com/info/publishing_adv.asp

